

Available online at www.sciencedirect.com

ScienceDirect

journal homepage: www.elsevier.com/locate/ajur

Original Article

Female anterior wall onlay urethroplasty with lower lip buccal mucosal graft: Importance of the laterally extended incision

Maryam Emami ^a, Pejman Shadpour ^b, Koosha Kamali ^c,
Nima Narimani ^{c,*}, Jalil Hosseini ^d

^a Hasheminejad Kidney Center, Iran University of Medical Sciences, Tehran, Iran

^b Hasheminejad Kidney Center (HKC), Hospital Management Research Center, Iran University of Medical Sciences, Tehran, Iran

^c Hasheminejad Kidney Center (HKC), Iran University of Medical Sciences, Tehran, Iran

^d Men's Health and Reproductive Health Research Center, Shahid Beheshti University of Medical Sciences, Tehran, Iran

Received 3 November 2020; received in revised form 13 May 2021; accepted 7 September 2021
Available online 11 April 2022

KEYWORDS

Female urethroplasty;
Buccal graft;
Dorsal;
Anterior wall onlay;
Urethral stricture;
Video-urodynamics

Abstract *Objective:* To describe the outcome of female anterior wall (pubic side) onlay urethroplasty with buccal mucosal graft using laterally extended surgical dissection in patients with previously failed minimally invasive techniques.

Methods: From January 2016 to April 2018, 17 symptomatic patients with previously failed minimally invasive procedures were enrolled in the study. The diagnosis of urethral stricture was confirmed based on a combination of patients' symptoms, post-void residual urine, video-urodynamics, and cystoscopy. Urethroplasty with lower lip mucosal graft was performed using the modified laterally extended dissection. Patients were evaluated pre-operatively and 12-month post-operatively with the American Urological Association symptom score, post-void residual urine, and maximum flow rate.

Results: Despite the previously failed minimally invasive procedures, urethroplasty with lower lip buccal graft and laterally extended dissection resulted in favorable outcomes (success rate = 94%). The mean ± standard deviation of American urological association symptom score improved from pre-operative levels at the 12-month post-operative follow-up (25.82 ± 3.97 to 10.88 ± 5.57); so did postvoid residual urine (71.12 ± 74.98 mL to 15.00 ± 28.30 mL), and maximum flow rate (7.88 ± 1.72 mL/s to 25.82 ± 5.59 mL/s) with all statistically significant ($p < 0.05$).

* Corresponding author.

E-mail addresses: nima_dr2001@yahoo.com, narimani.n@iums.ac.ir (N. Narimani).

Peer review under responsibility of Tongji University.

<https://doi.org/10.1016/j.ajur.2022.04.002>

2214-3882/© 2023 Editorial Office of Asian Journal of Urology. Production and hosting by Elsevier B.V. This is an open access article under the CC BY-NC-ND license (<http://creativecommons.org/licenses/by-nc-nd/4.0/>).

Conclusion: The current study showed that female urethroplasty with buccal graft could be highly successful in experienced hands. An anterior approach could be superior to the posterior one due to higher mechanical support and lower sacculation rate. A laterally extended incision may improve visualization and better graft placement by providing wider working space. The results should be evaluated in the future studies with larger sample size.

© 2023 Editorial Office of Asian Journal of Urology. Production and hosting by Elsevier B.V. This is an open access article under the CC BY-NC-ND license (<http://creativecommons.org/licenses/by-nc-nd/4.0/>).

1. Introduction

Female urethral stricture is an uncommon condition with an estimated prevalence of 4%–13% in women with bladder outlet obstruction [1,2]. It may be caused due to inflammation, infection, iatrogenic and non-iatrogenic trauma, radiation, etc. [3]. Non-specific clinical presentations, such as recurrent urinary tract infection, storage and obstructive lower urinary tract symptoms, lack of a standard definition, different diagnostic tools, and various therapeutic options, give rise to controversy in the management of female urethral stricture [2] (Fig. 1).

Various diagnostic methods such as post-void residual urine (PVR), uroflowmetry or urodynamic study, video-urodynamics study, cystourethroscopy, and urethral calibration have been proposed for the diagnosis of female urethral stricture [4]. Given the limitations of all these modalities, the combination of two or even more techniques are usually employed for confirmation of the diagnosis [5].

The main treatment options consist of minimally invasive procedures and urethral reconstruction. The minimally invasive methods include urethral dilation (UD) [6], endoscopic incision with laser (incision at 9 o'clock and 3 o'clock positions) [7], and internal urethrotomy [8]. The success rates of UD, which was once considered as the mainstay treatment in urethral stricture, are about 40%–50% and should be used only as initial treatment. In patients with failed UD, multiple dilation attempts may be of limited value [9].

Urethral reconstruction may become the treatment of choice in stricture recurrence following the failure of minimally invasive procedures. Primary reconstruction even through a symphysiotomy, if needed for exposure [10] and the use of flaps and grafts have all been proposed [11]. Different materials (e.g., vaginal and genital mucosal graft or flap, bladder mucosal flap, and oral mucosal graft) have been reported for augmentation urethroplasty. However, given the heterogeneity in success rates, the graft of choice is yet to be defined [2]. This ambiguity is understandable owing to the small sample size and difference in surgical technique in the very few reports on utilizing grafts for female urethral strictures, and even fewer reports including follow-up. Augmentation urethroplasty is conceivable through two basic approaches: anterior (pubic) and posterior (vaginal). The posterior approach entails minimum urethral mobilization, but higher chance of graft sacculation and urethrovaginal fistula formation in return [12]. Such an approach appears to be more convenient than the anterior one, and more familiar as it is commonly performed in other vaginal procedures [3]. In contrast, the anterior approach potentially offers the advantage of providing excellent mechanical support and minimal graft sacculation, and a well vascularized bed for grafting [12]. However, the anterior approach may theoretically carry a greater risk for injuring the neurovascular supply to the clitoris [13]. In addition, the limited space between the urethra and clitoris, hence the small working field may pose another challenge in this method. We proposed that an extended lateral dissection could overcome this limitation

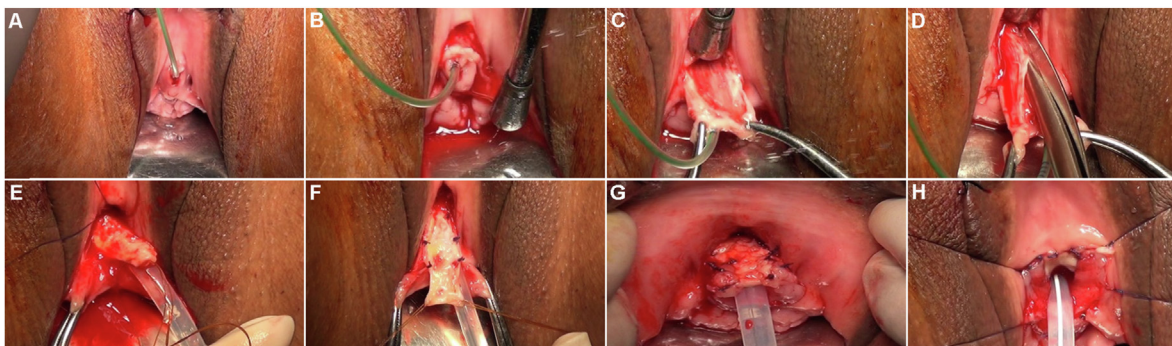


Figure 1 Surgical technique. (A) Initial appearance; (B) Circumferential mucosal incision around the meatus with ample lateral extension at 3 and 9 o'clock positions; (C) Suprameatal dissection, extruding the upper aspect of the urethra; (D) Twelve o'clock incision of the urethra extending into the normal proximal mucosa (near the bladder neck); (E) Buccal mucosal grafting; (F and G) Securing graft to the urethral edges with Vicryl suture; (H) Final view while anchoring the urethra to surrounding tissue.

of the anterior approach, and afford enough space for graft insertion.

Herein, we report our experience with female anterior wall urethroplasty using buccal mucosal graft (BMG) performed in a single center along with minimum of 12-months follow-up.

2. Methods

After being confirmed by our institutional review board (Iran University of Medical Sciences, IR.IUMS.REC.1399.318), the patients' records were reviewed retrospectively and outpatient clinical data on a case series of 17 female urethroplasties utilizing BMG including written consent to surgery and access to anonymized data, were collected prospectively. Hasheminejad Kidney Center is a university hospital functioning as the national referral center for urology, nephrology, and kidney transplants. As part of our mission, we have actively engaged in advanced reconstructive procedures in female urology including many cases with complicated urethral strictures, referred from all over the country.

The concluded diagnosis of urethral stricture was made based on a combination of symptoms and complaints, cystoscopy, and urethral calibration, backed by residual urine measurement, ultrasonography, and videourodynamics study findings.

Patients had bothersome lower urinary tract symptoms (irritative and obstructive) and/or urge incontinence, history of recurrent urinary tract infection, and multiple (at least two) urethral procedures (UD and/or internal urethrotomy) before referral. Symptom severity was assessed by the American Urological Association (AUA) symptom score for urethral stricture and graded as mild (0–7), moderate (8–19), or severe (20–35) [14].

All patients underwent a thorough pelvic and genitourinary examination performed by one of the authors (Emami M) with special attention to pelvic organ prolapse and lichen sclerosis, and those with either were excluded from this report. After residual urine measurement and ultrasonography, all patients underwent videourodynamics study as part of their assessments. High detrusor pressure at maximum flow (>25 cm H₂O, 1 cm H₂O=98.0665 Pa) with a low flow rate (<12 mL/s) was suggestive of obstruction [5]. In the fluoroscopy section, although voiding in standing position is impractical for the majority of women, and image clarity may decrease in sitting position, anatomical narrowing of the urethral lumen in combination with proximal urethral ballooning during voiding further supported the diagnosis [6]. Diagnosis of stricture was ultimately confirmed by cystoscopy for visualizing the anatomy.

In cystourethroscopy, resistance during the passage of a 17 Fr flexible cystoscope via the urethra is considered as urethral stricture [15], and special attention must be given to the length and location of the stricture. Measurement of urethral diameter with Nelaton catheter (urethral calibration) was also performed at the time of cystoscopy. Since the patients had complex urethral stricture with multiple previous urethral procedures, a 17.5 Fr cystoscope (Richard Wolf GmbH, Knittlingen, Germany) could not be passed

through the urethra. Therefore, a 8 Fr semirigid pediatric cystoscope (Richard Wolf GmbH, Knittlingen, Germany) was used for urethral assessment (though not possible in very severe cases, at the beginning of the procedure). Moreover, the size of the largest urethral catheter which could be passed in each case was recorded.

2.1. Surgical technique

Urethroplasty includes harvesting a BMG adequately as described elsewhere. Harvesting the BMG from inferior lip is easy to perform and does not carry any risk of Stenson's duct injury. Moreover, in the current study, the graft site was deliberately left unsutured, to heal rapidly by secondary intention as proposed in the literature [16]. We have found the following technical steps to be helpful: submucosal injection with diluted (1:100 000) epinephrine, preferential use of the lower lip as the donor site, staying as close as possible to the mucosa, avoiding electrocautery before removing the graft, and aggressive de-fattening. Urethroplasty proceeds in the dorsal lithotomy position. With a neonatal 6 Fr cystoscope, the approximate size of the stricture was estimated, along with its distance from the bladder neck.

A small urethral catheter was passed through the urethra to guide dissection starting with a circumferential incision beginning above the meatus. The supra meatal plane was developed close to the urethra from 9 o'clock to 3 o'clock between mucosa and underlying tissue in order to obtain enough lateral space. By lateral extended incision, we implied the standard semilunar dissection from 9 o'clock to 3 o'clock plus subpubic extension on both sides in the coronal plane in addition to generous deep dissection to reach the bladder neck. The lateral spaces provided essential workspace for proper mobilization of the dorsal aspect of urethra, and further provided ample platform for securing the graft later on in the operation. The urethra was then incised at 12 o'clock (anterior aspect) to reach normal urethral mucosa (near the bladder neck). This is in contrast to the previously described technique which stopped the urethral incision upon reaching a dilated proximal urethra [17]. The dissection was extended through the fibrosis to attain normal urethral caliber (at least 20 Fr on intraoperative urethral calibration). Care was taken to preserve the periurethral sphincteric mechanism. The oral graft was then placed and sutured across the incision with interrupted 4/0 Vicryl at the lateral edges. The new urethra was tacked to the underlying tissue with the same material. An 18 Fr Foley catheter was left indwelling for 3 weeks.

Patients were followed up clinically through regular scheduled postoperative visits for 12 months (at minimum) and beyond that point on walk-in postoperative visits. Each time the patient was evaluated by the above-mentioned questionnaire, uroflowmetry, and ultrasonography (for PVR). In addition, patients' satisfaction with the surgical outcome was assessed by the Patient Global Impression of Improvement questionnaire and graded by its 5 score scale as: very much better (score=1), much better (score=2), a little better (score=3), no change (score=4), or worse than before (score=5).

Surgical failure was defined as urethral re-stenosis confirmed by cystourethroscopy in patients with recurrence of urinary symptoms with/without decrease in uroflowmetric maximum flow rate.

2.2. Statistical analysis

The SPSS software (Version 22.0; IBM corp., Armonk, NY, USA) was used for data analysis. The normality of data distribution was evaluated by Kolmogorov-Smirnov test. Variables with normal distribution were evaluated with paired *t*-test. Wilcoxon signed-rank test was used for non-normally distributed data. The data are presented as mean±standard deviation (SD) and range. The difference is considered as statistically significant if $p < 0.05$.

3. Results

From January 2016 to April 2018, 17 patients were included in this series (age: mean±SD 54.8±7.0 years, range 42–65 years; body mass index: mean±SD 27.0±1.8 kg/m², range 24–31 kg/m²). The mean follow-up time with SD was 17.35±3.66 months (range 12–23 months). The majority of these cases were thought to have resulted iatrogenically from gynecologic surgery followed by obstetric complications. No cause was traceable in two which were considered idiopathic. Ten patients (58.8%) with history of recurrent urinary tract infection had multiple failed urethral procedures in the past (median of 3 interventions, range 2–5 times). The mean±SD for duration of our procedure was 104.41±21.85 min (range 70–150 min) for the urethroplasty section without any major complications or need for blood transfusion. Minor complaints at harvest site (e.g., pain, difficult mouth opening, and perioral numbness) were common during in-hospital stay which resolved in the post-operative follow-up within 6 months. The width and length of graft size were 1.53±0.14 cm (range 1.4–2.0 cm) and 4.21±0.24 cm (range 3.8–4.7 cm), respectively. The stricture length was 3.19±0.31 cm (range 2.7–4.0 cm). The location of the stricture was in distal two thirds ($n=5$, 29.4%), proximal two thirds ($n=2$, 11.8%) and total urethra ($n=10$, 58.8%) of the patients.

The AUA symptom score, residual bladder urine, and peak flow rate improved significantly and maintained 12 months post-operatively. Table 1 summarizes our findings at the 12th month visit of the studied patients. The success rate of female urethroplasty with buccal graft in the current study was 94% after 12 months of follow-up.

4. Discussion

Female urethral stricture is a rare entity and thus there are limited data on its surgical success rate. Most of the reported series include a small number of participants and diverse surgical techniques which make it difficult to evaluate the surgical success rate of each single approach [18]. To the best of our knowledge, this is the largest reported series of female anterior wall onlay urethroplasty with lower lip BMG to date, performed at one center. We chose this approach because buccal mucosa is an excellent graft for urethroplasty, as it is elastic, hairless, and adapted to a moist environment. On the other hand, using the anterior instead of posterior approach may decrease the risk of graft weakening and fistula or urethrocele formation [19]. Reports on complications associated with the lower lip donor site are scarce. In a small series of 24 patients, Kamp and colleagues [20] divided their patients into two groups, one including 12 patients with lower lip or mixed inner cheek and lower lip graft, and the other 12 with inner cheek (on or both cheeks) graft only. They stated lower morbidity with the inner cheek in comparison with lower lip donor site. However, their study included heterogenous patients (in lower lip group), who might have needed larger size grafts (extending from lower lip to the inner cheek) which in turn may increase the morbidity at the donor site [20]. In our study, we found no lasting morbidity in donor site. This may be due to either small graft size harvested from the lower lip or modest sample size.

In their review article, Markiewicz and colleagues [21] showed total complication rates of 3% and 4% for lower lip and buccal graft site, respectively, which was not statistically different. They stated that neurosensory deficit (manifested as perioral numbness) associated with lower lip graft may last up to 10 months, but ultimately resolved.

In this study, all patients had previously failed multiple sessions of minimally-invasive urethral procedures, despite the reported low success rate. Our results showed that although the success rate of female urethroplasty with buccal graft was far better than UD (mean success rate was 47%) [12], it is still underutilized. This may be due to simplicity of the minimally invasive techniques, associated financial considerations (income of an office-based procedure), and complexity of female urethroplasty.

Nevertheless, our success rate after 12 months of follow-up was higher than those reported previously (pooled success rate of 83% [18] and 89% [22] from previous studies). Patients showed significant post-surgical

Table 1 Pre- and post-operative AUA symptom score, Q_{max} , and PVR (mean±SD [range]).

Status	AUA symptom score	Q_{max} , mL/s	PVR, mL
Pre-operative	25.82±3.97 (18–34)	7.88±1.72 (5–10)	71.12±74.98 (0–250)
Post-operative	10.88±5.57 (4–25)	25.82±5.59 (17–37)	15.00±28.30 (0–100)
<i>p</i> -Value	<0.001 ^a	<0.001 ^a	0.001 ^b

AUA, American Urological Association; Q_{max} , maximum flow rate; PVR, post-void residual urine; SD, standard deviation.

^a Paired *t*-test.

^b Wilcoxon signed-rank test.

decrease in AUA symptom score, and expressed high satisfaction for the surgical results; 47.1% and 41.2% of the patients selected “very much better” and “much better”, respectively.

Satisfaction with this surgery may be partly due to the surgical technique. A laterally extended dissection may lead to greater working space, better visualization, and excellent graft placement, even beyond the site of the stricture, close to the bladder neck. Although lateral dissection may theoretically increase the chance of urinary incontinence, all patients in the current study remained continent. It seems that continence may be preserved observing meticulous, careful dissection.

A multi-center retrospective study on 39 patients with buccal graft urethroplasty (by six different surgeons) showed a success rate of 77% [18]. Besides extensive fibrosis due to previous urethral procedures, difference in surgeon experience and technique may be responsible for this lower success rate.

Goel and colleagues [23] and Powell and Daniels [24] in their retrospective studies on six and eight cases of dorsal urethroplasty with buccal graft showed a success rate of 67% and 62.5%, retrospectively. In contrary, Blaivas et al. [15] and Kowalik et al. [25] in their retrospective studies of four and three patients, stated a success rate of 100%. This difference may be due to the small number of subjects and difference in the applied surgical techniques.

In a recent systematic review and meta-analysis of 12 studies, Sarin and colleagues [22] stated a success rate of 89% for female urethroplasty with BMG at 19 months follow-up. Apart from surgical points of technique, our higher success rate may owe to the stated technical points, but also may have to do with the comparatively smaller sample size. As for any reconstruction of strictures, success may decline to the findings of other authors on longer follow-up.

In the present study, only one patient developed urethral stricture presenting as decreased urinary force and residue feeling 3 months post-operatively. At the time of recurrence, her PVR, peak flow rate, and AUA symptom score were 100 mL, 9 mL/s, and 25, respectively. The diagnosis was further confirmed with cystourethroscopy which

showed restenosis proximal to the graft site. She was managed with UD twice in 2 consecutive months. The results of dilation following failed urethroplasty have been reported by some authors [23,26], although redo urethroplasty has also been performed by others [15,18]. Our patient was reluctant for another reconstructive surgery. Table 2 compares the results of previous reports with the present series.

We followed our patients by non-invasive means including AUA symptom scoring, sonographic estimation of post void residual and uroflowmetry for the initial 12 months. This is in contrast to some other studies which had followed their participants with invasive methods such as cystourethroscopy [18]. Since cystourethroscopy itself is considered a risk factor for urethral stricture [27,28], we avoided such an approach. Instead, follow-up cystoscopy was reserved for symptomatic patients with increased residue and/or low maximum flow rate.

Our study represents a single center case series, which was retrospective in nature and included a limited number of cases with no control group. Given the scarcity of female urethral stricture and the overall low referral rate for female urethroplasty, efforts for patient randomization into different groups may inevitably require multicenter studies. On the other hand, the majority of our patients were not overweight (mean body mass index: 27.0 kg/m²), and efficacy of our proposed surgical modifications shall stand to be corroborated in obese patients in the future, as these are usually more challenging cases.

5. Conclusion

The current study showed that female urethroplasty with buccal graft had a high success rate in patients with previous failed minimally invasive techniques. The anterior approach may provide better mechanical support and lower sacculation rate, but small working space. We strongly recommend a laterally extended incision for improved visualization, greater working space, and better graft placement. However, our findings should be further investigated in larger studies in the future.

Table 2 Female urethroplasty with buccal graft series.

Study	Case, <i>n</i>	Follow-up, mean (range), month	Success rate, %	Method
Hampson et al. [18]	39	33 (7–107)	77.0	Dorsal buccal graft
Powell and Daniels [24]	6	18	67.0	Dorsal buccal graft
Mukhtar et al. [29]	22	22 (5–61)	95.5	Ventral buccal graft
Kowalik et al. [25]	4	34 (10–75)	100.0	Dorsal buccal graft
Goel et al. [23]	8	15	62.5	Dorsal buccal graft
Blaivas et al. [15]	3	18 (15–48)	100.0	Dorsal buccal graft
Onol et al. [30]	6	17	83.0	Dorsal, ventral, and modified buccal graft
Castillo et al. [31]	2	18	100.0	Dorsal buccal graft
Sharma et al. [26]	15	12	93.3	Dorsal lingual mucosal graft
Migliari et al. [32]	3	6	100.0	Dorsal buccal graft
Present study	17	12	94.0	Lower lip buccal graft

Authors contributions

Study concept and design: Maryam Emami, Pejman Shadpour, Nima Narimani.

Data acquisition: Nima Narimani, Maryam Emami.

Data analysis: Nima Narimani.

Drafting of manuscript: Nima Narimani, Pejman Shadpour, Koosha Kamali.

Critical revision of the manuscript: Jalil Hosseini.

Conflicts of interest

The authors declare no conflict of interest.

Acknowledgement

We would like to thank Dr. Nasrin Borumandnia from Urology and Nephrology Research Center, Shahid Beheshti University of Medical Sciences, Tehran, Iran, epidemiologist, for helping us in the revision of the final manuscript.

References

- [1] Spilotros M, Malde S, Solomon E, Grewal M, Mukhtar BM, Pakzad M, et al. Female urethral stricture: a contemporary series. *World J Urol* 2017;35:991–5.
- [2] West C, Lawrence A. Female urethroplasty: contemporary thinking. *World J Urol* 2019;37:619–29.
- [3] Ackerman AL, Blaivas J, Anger JT. Female urethral reconstruction. *Curr Bladder Dysfunct Rep* 2010;5:225–32.
- [4] Waterloos M, Verla W. Female urethroplasty: a practical guide emphasizing diagnosis and surgical treatment of female urethral stricture disease. *Biomed Res Int* 2019;2019:6715257. <https://doi.org/10.1155/2019/6715257>.
- [5] Osman NI, Chapple CR. Contemporary surgical management of female urethral stricture disease. *Curr Opin Urol* 2015;25:341–5.
- [6] Popat S, Zimmern PE. Long-term management of luminal urethral stricture in women. *Int Urogynecol J* 2016;27:1735–41.
- [7] Rosenblum N, Nitti VW. Female urethral reconstruction. *Urol Clin North Am* 2011;38:55–64.
- [8] Grivas N, Tsimaris I, Makatsori A, Hastazeris K, Kafarakis V, Stavropoulos NE. The effectiveness of Otis urethrotomy combined with six weeks urethral dilations until 40 Fr in the treatment of bladder outlet obstruction in women: a prospective study. *Urol J* 2014;10:1063–6.
- [9] Hoag N, Chee J. Surgical management of female urethral strictures. *Transl Androl Urol* 2017;6:576–80. <https://doi.org/10.21037/tau.2017.01.20>.
- [10] Basiri ASP, Moradi MR, Ahmadiania H, Madaen K. Symphysiotomy: a viable approach for delayed management of posterior urethral injuries in children. *J Urol* 2002;2166–9.
- [11] Aldamanhori R, Inman R. The treatment of complex female urethral pathology. *Asian J Urol* 2018;5:160–3.
- [12] Osman NI, Mangera A, Chapple CR. A systematic review of surgical techniques used in the treatment of female urethral stricture. *Eur Urol* 2013;64:965–73.
- [13] Petrikovets A, Sun HH, Kiechle J, Chapman GC, Gonzalez CM, Hijaz A. Ventral-onlay buccal mucosal graft urethroplasty for the treatment of female urethral stricture: a step-by-step video for female pelvic reconstructive surgeons. *Int Urogynecol J* 2019;30:2191–3.
- [14] Keegan KA, Nanigian DK, Stone AR. Female urethral stricture disease. *Curr Urol Rep* 2008;9:419–23.
- [15] Blaivas JG, Santos JA, Tsui JF, Deibert CM, Rutman MP, Purohit RS, et al. Management of urethral stricture in women. *J Urol* 2012;188:1778–82.
- [16] Muruganandam K, Dubey D, Gulia AK, Mandhani A, Srivastava A, Kapoor R, et al. Closure versus nonclosure of buccal mucosal graft harvest site: a prospective randomized study on post operative morbidity. *Indian J Urol* 2009;25:72–5.
- [17] Manasa T, Khattar N, Tripathi M, Varshney A, Goel H, Sood R. Dorsal onlay graft urethroplasty for female urethral stricture improves sexual function: short-term results of a prospective study using vaginal graft. *Indian J Urol* 2019;35:267–72.
- [18] Hampson LA, Myers JB, Vanni AJ, Virasoro R, Smith 3rd TG, Capiel L, et al. Dorsal buccal graft urethroplasty in female urethral stricture disease: a multi-center experience. *Transl Androl Urol* 2019;8: 56–12.
- [19] Rehder P, Glodny B, Pichler R, Exeli L, Kerschbaumer A, Mitterberger MJ. Dorsal urethroplasty with labia minora skin graft for female urethral strictures. *BJU Int* 2010;106:1211–4.
- [20] Kamp S, Knoll T, Osman M, Hacker A, Michel MS, Alken P. Donor-site morbidity in buccal mucosa urethroplasty: lower lip or inner cheek? *BJU Int* 2005;96:619–23.
- [21] Markiewicz MR, DeSantis JL, Margarone 3rd JE, Pogrel MA, Chuang SK. Morbidity associated with oral mucosa harvest for urological reconstruction: an overview. *J Oral Maxillofac Surg* 2008;66:739–44.
- [22] Sarin I, Narain TA, Panwar VK, Bhadoria AS, Goldman HB, Mittal A. Deciphering the enigma of female urethral strictures: a systematic review and meta-analysis of management modalities. *Neurourol Urodyn* 2021;40:65–79.
- [23] Goel A, Paul S, Dalela D, Sankhwar P, Sankhwar SN, Singh V. Dorsal onlay buccal mucosal graft urethroplasty in female urethral stricture disease: a single-center experience. *Int Urogynecol J* 2014;25:525–30.
- [24] Powell CR, Daniels D. Dorsal onlay buccal urethroplasty in the female is associated with high quality of life using validated lower urinary tract symptom instruments. *Urol Pract* 2017;4: 48–53.
- [25] Kowalik C, Stoffel JT, Zinman L, Vanni AJ, Buckley JC. Intermediate outcomes after female urethral reconstruction: graft vs. flap. *Urology* 2014;83:1181–5.
- [26] Sharma GK, Pandey A, Bansal H, Swain S, Das SK, Trivedi S, et al. Dorsal onlay lingual mucosal graft urethroplasty for urethral strictures in women. *BJU Int* 2010;105:1309–12.
- [27] Lumen N, Hoebeke P, Willemsen P, De Troyer B, Pieters R, Oosterlinck W. Etiology of urethral stricture disease in the 21st century. *J Urol* 2009;182:983–7.
- [28] Hoag N, Gani J, Chee J. Vaginal-sparing ventral buccal mucosal graft urethroplasty for female urethral stricture: a novel modification of surgical technique. *Investig Clin Urol* 2016;57:298–302.
- [29] Mukhtar BMB, Spilotros M, Malde S, Greenwell TJ. Ventral-onlay buccal mucosa graft substitution urethroplasty for urethral stricture in women. *BJU Int* 2017;120:710–6.
- [30] Onol FF, Antar B, Kose O, Erdem MR, Onol SY. Techniques and results of urethroplasty for female urethral strictures: our experience with 17 patients. *Urology* 2011;77:1318–24.
- [31] Castillo OA, Sepulveda F, Fera-Flores MA. Urethroplasty with dorsal oral mucosa graft in female urethral stenosis. *Actas Urol Esp* 2011;35:246–9.
- [32] Migliari R, Leone P, Berdondini E, De Angelis M, Barbagli G, Palminteri E. Dorsal buccal mucosa graft urethroplasty for female urethral strictures. *J Urol* 2006;176:1473–6.